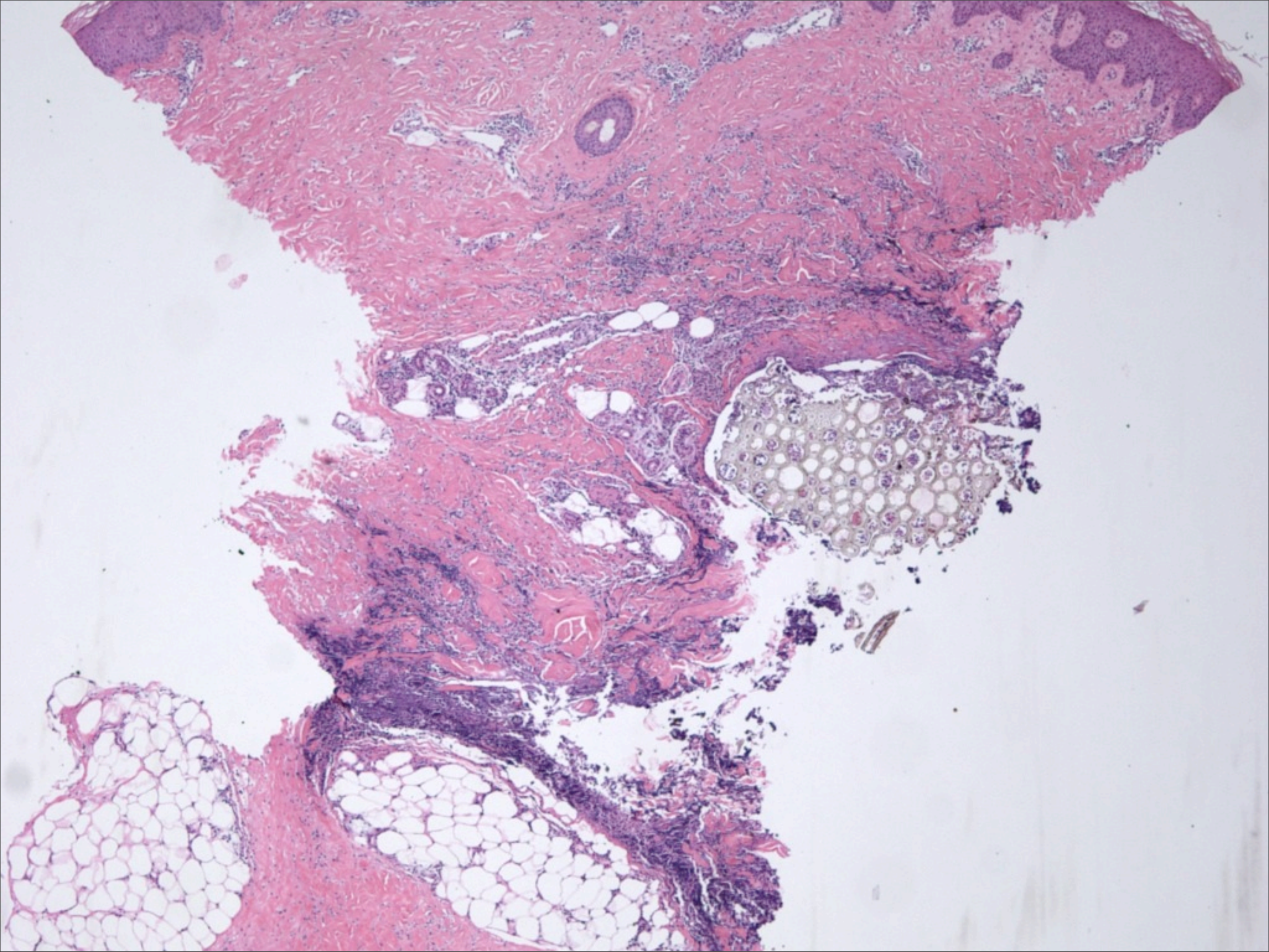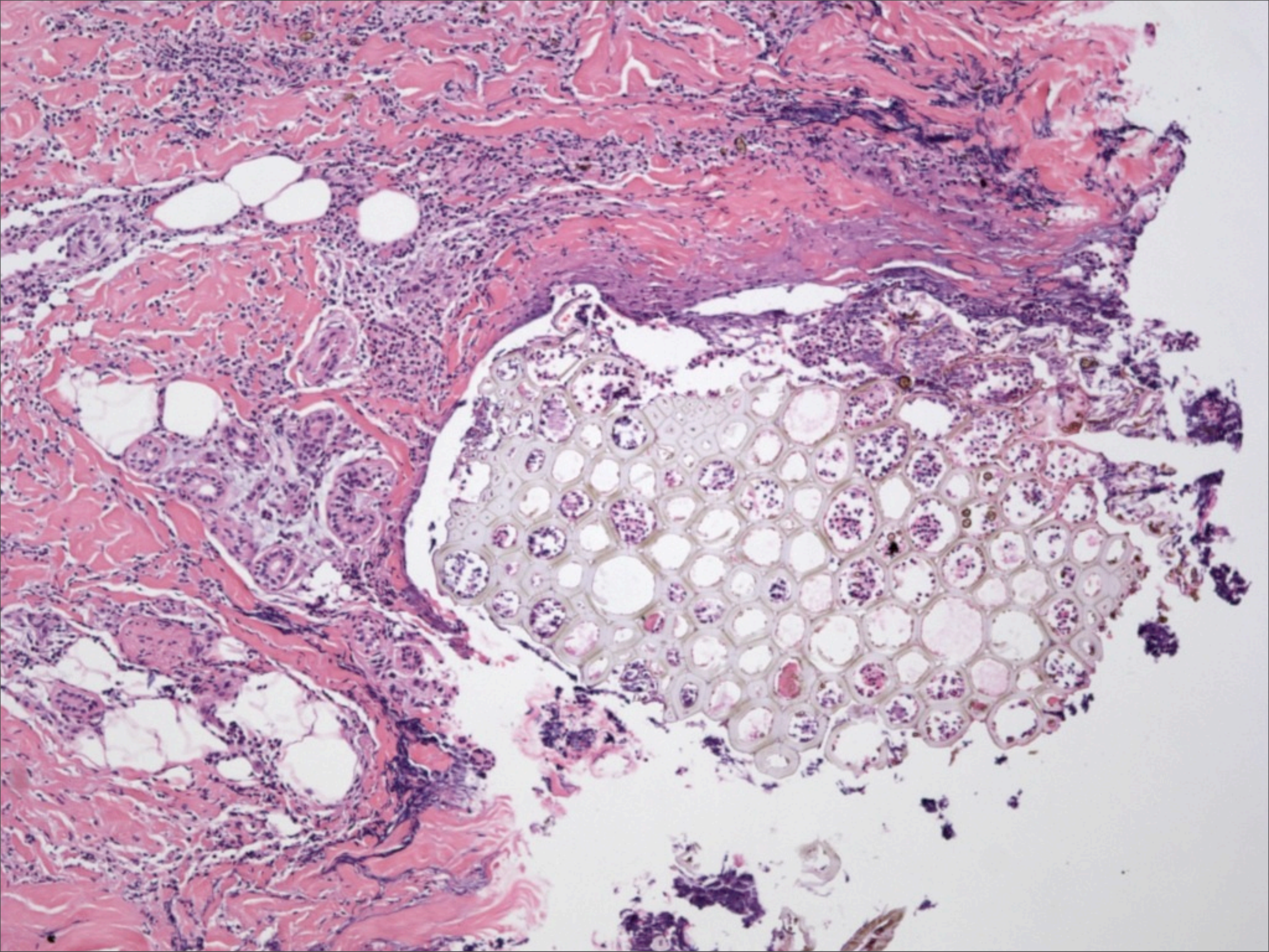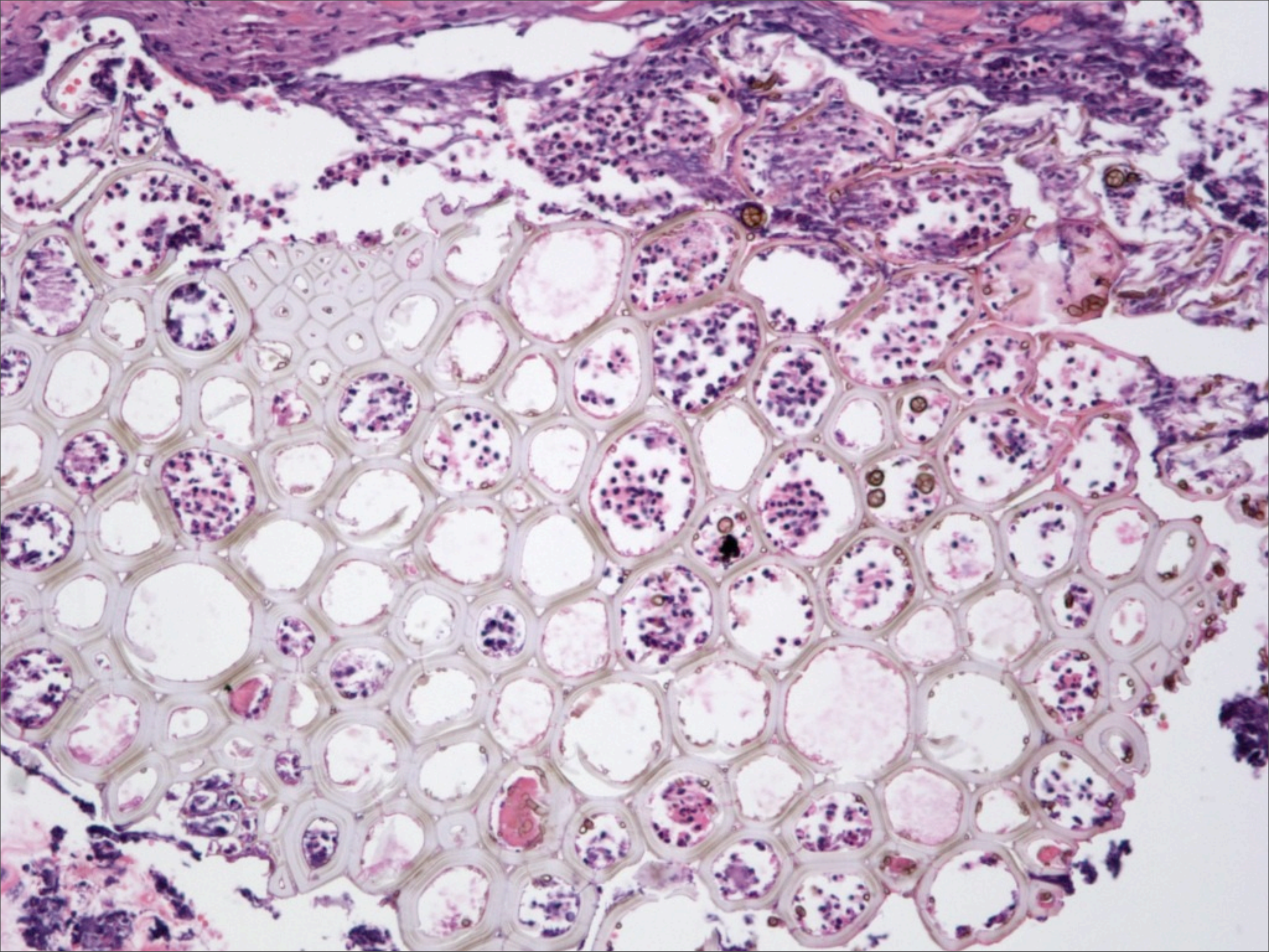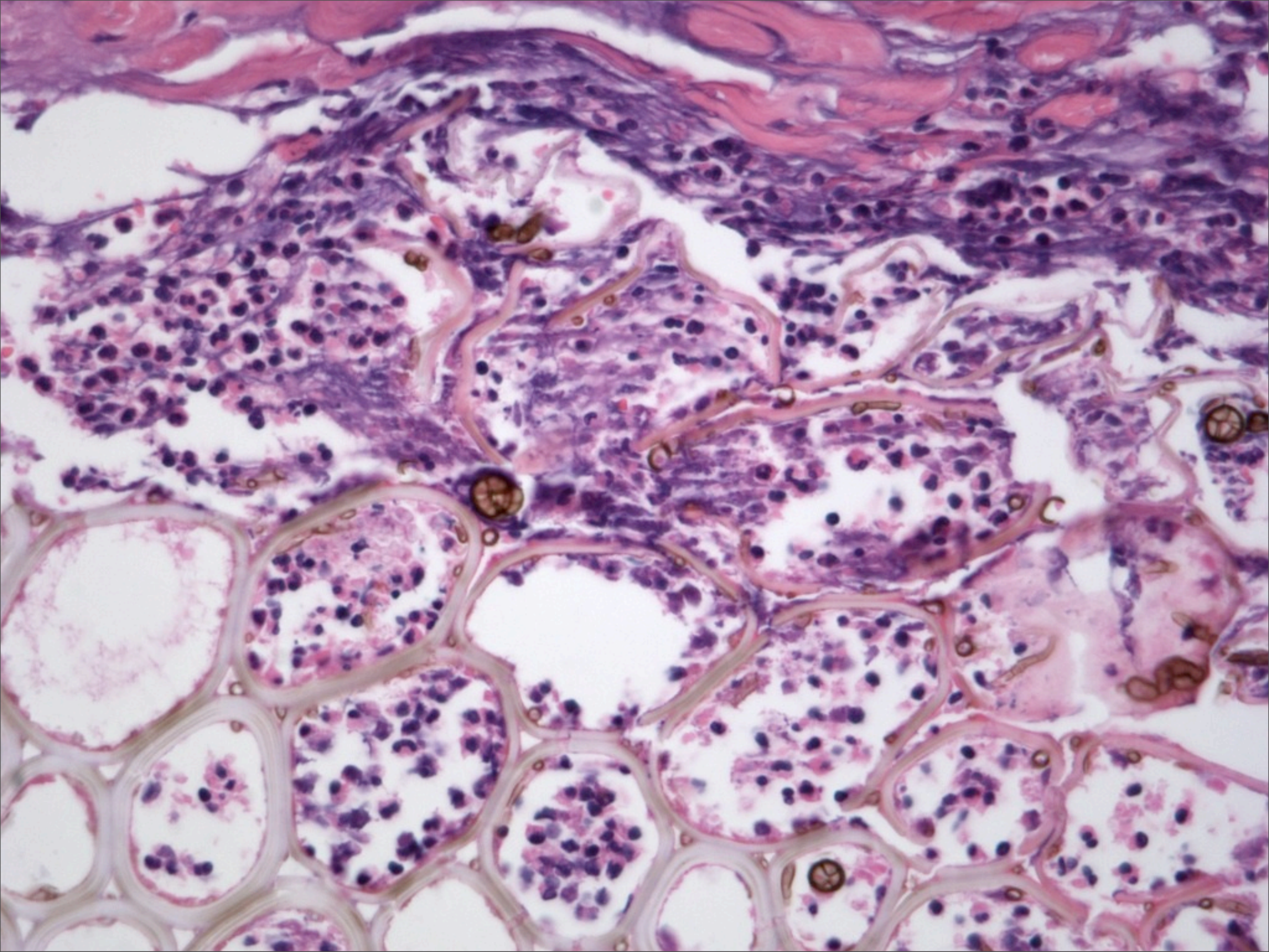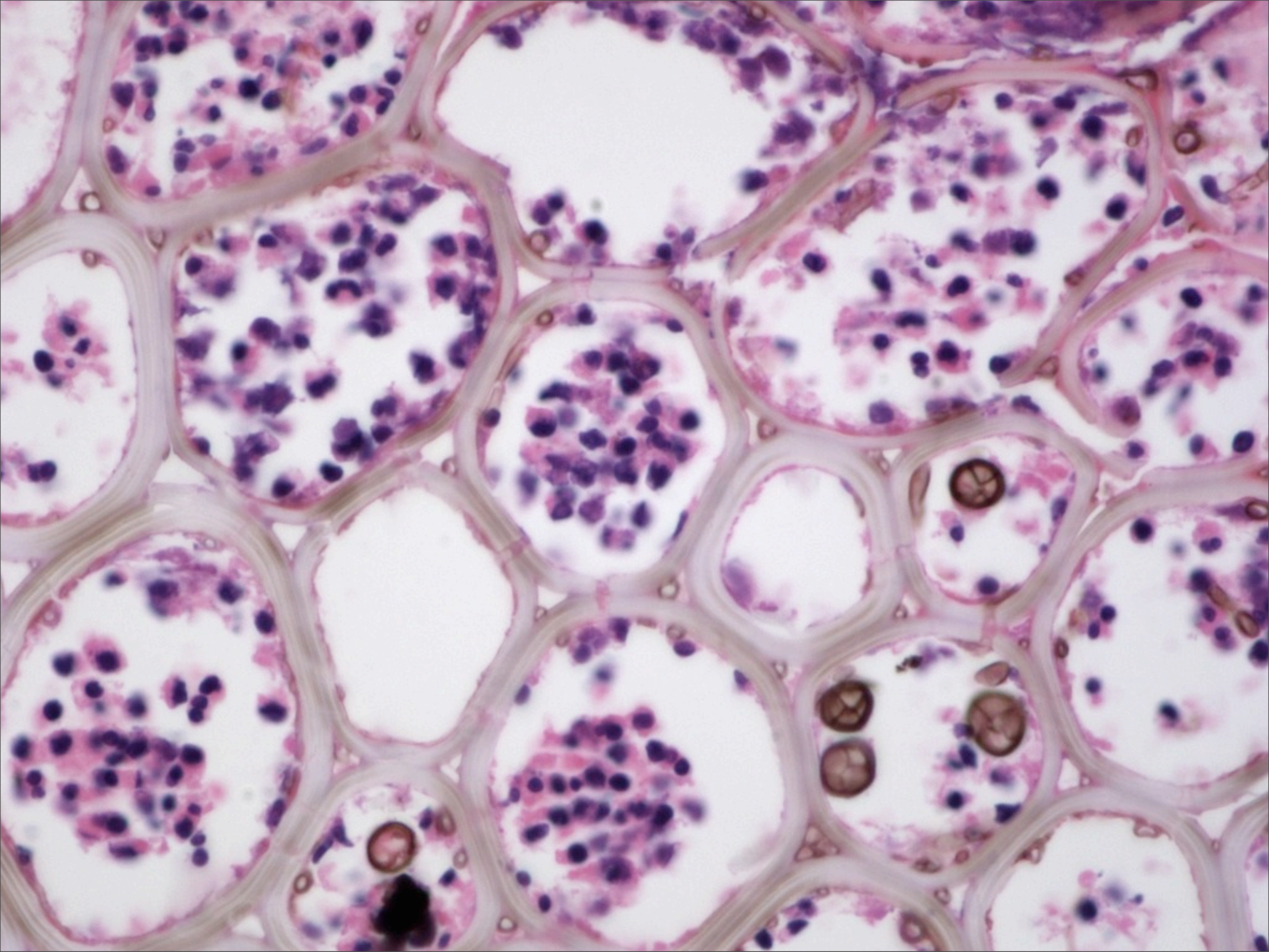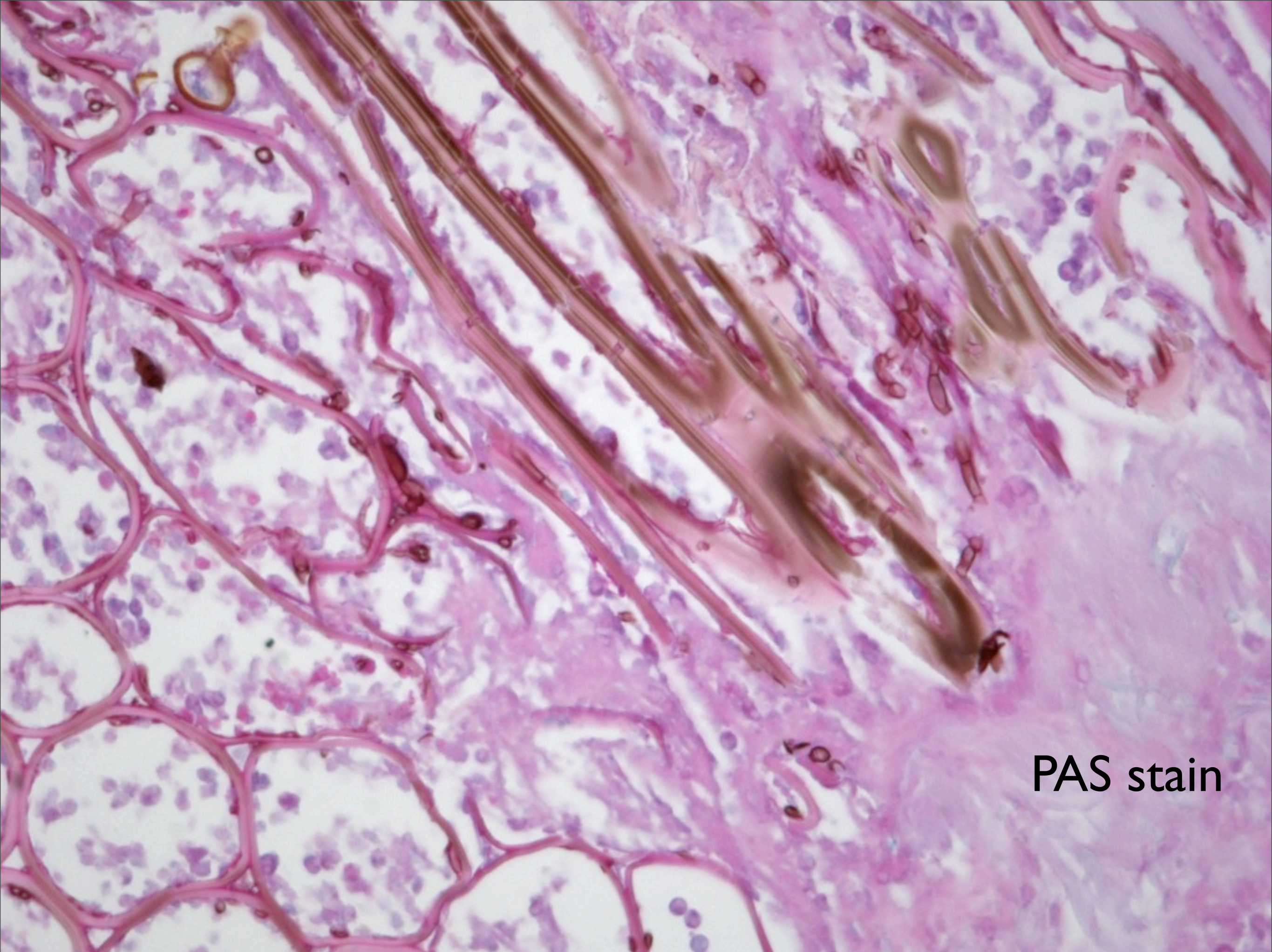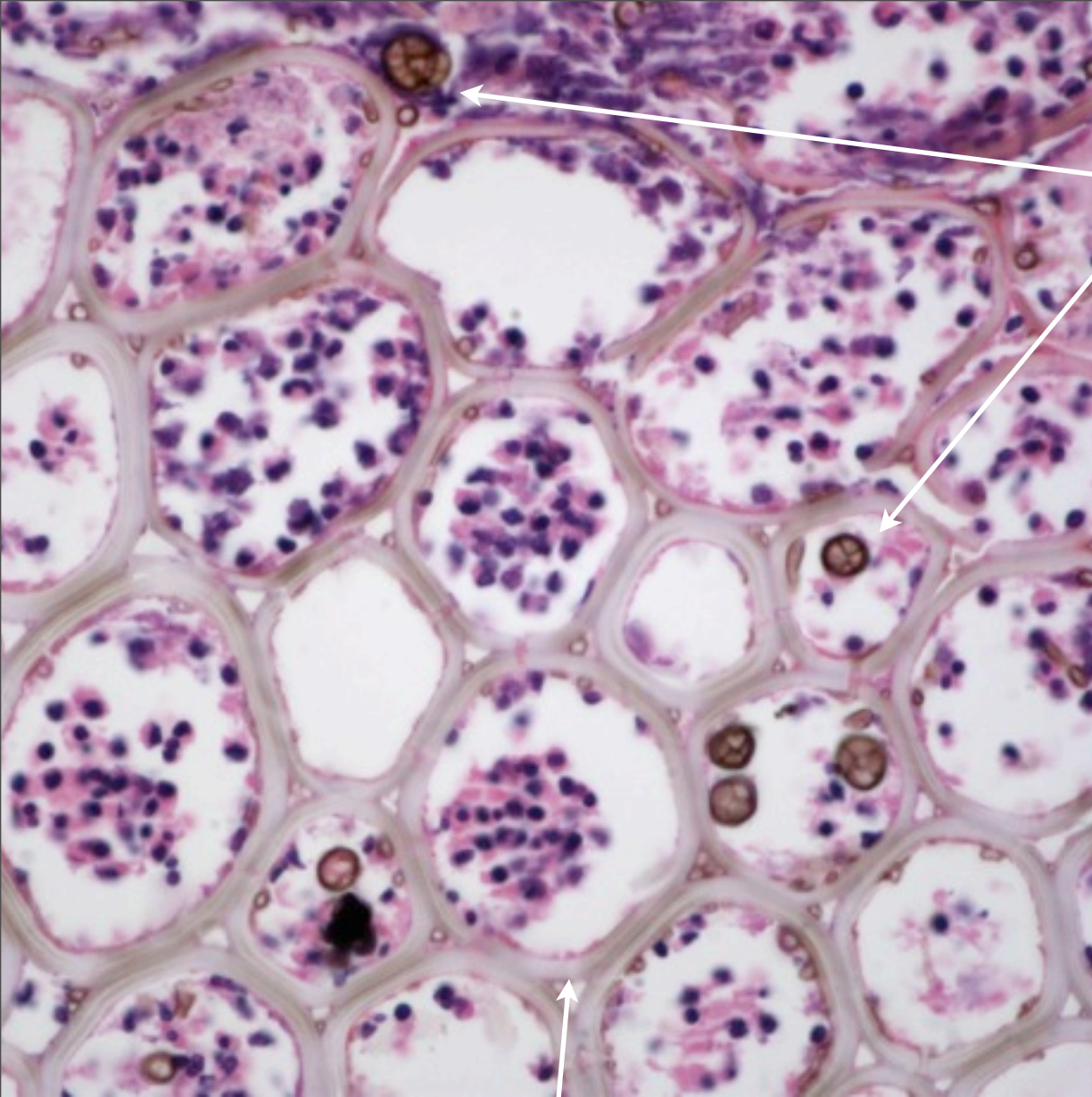


PAS stain

Chromomycosis



Medlar bodies
(Sclerotic Bodies)

Often associated with
splinter or foreign body